

Non-invasive assessment of intracranial arterial and respiratory pressure waves via the trans aural route.

*Jean-Pierre Lin , *Eric Rosenthal & **Robert Marchbanks

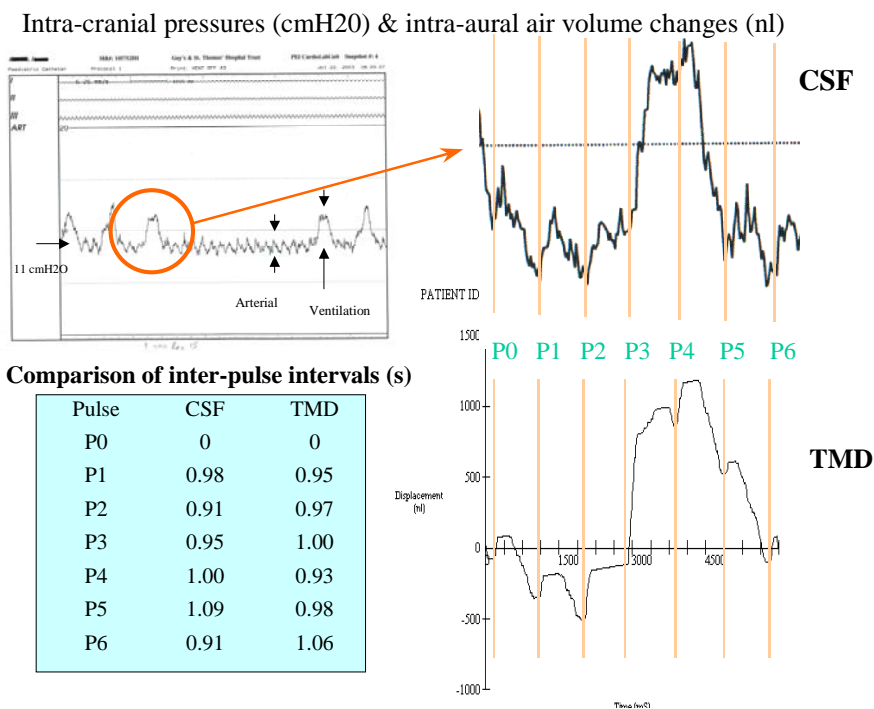
*Guy's & St Thomas' Foundation NHS Trust, London, UK

**Dept Medical Physics & Bioengineering, Southampton General Hospital, UK.

The clinical measurement of intracranial pressure usually requires invasive access to the cerebrospinal fluid compartment which is painful, hazardous in the unconscious patient and impractical for long-term follow-up studies.

The trans-aural route of intracranial pressure monitoring has been previously described (Marchbanks 1987, Samuel et al 1998).

Ethical permission was obtained for systematic study of trans-aural intracranial pressure measurements in children. A 16 year old girl with longstanding headache, papilloedema and congenital heart disease underwent general anaesthesia and mechanical ventilation for replacement of her cardiac pacemaker and an opportunistic lumbar puncture was performed



The continuous cerebrospinal fluid (CSF) pressure is shown with the arterial and mechanical ventilation waveforms indicated by arrows (top left) and enlarged (top right). The trans-aural (TMD) air volume changes (bottom right: nanolitres) clearly match the CSF arterial and ventilation pulse changes and the arterial interpulse intervals (P0-P6) are tabulated (bottom left). Ventilated CSF respiratory pressure waves of 3.6cmH2O compared with TMD volume displacements of 1684nl (peak-peak). This gives a CSF/TMD calibration factor of 0.021 mm saline / nl and the TMD will resolve displacements to less than 5nl or 0.10 mm saline.

This represents the first description of accurate intracranial respiratory and cardiovascular pulse waves via the trans-aural route in man.

Marchbanks, R.J., Reid, A., Martin, A.M., et al (1987) The effect of raised intracranial pressure on intracochlear fluid pressure: three case studies. *British Journal of Audiology*, 21, 127-130.

Samuel, M., Marchbanks, R.J. and Burge, D.M. (1998) Tympanic membrane displacement test in regular assessment of intracranial pressure in eight children with shunted hydrocephalus. *J Neurosurg* 88:983-995.